



Health | Wealth | Happiness

Date: 22<sup>nd</sup> January, 2026

To, Manager - Listing Compliance <b>National Stock Exchange of India Limited</b> 'Exchange Plaza'. C-1, Block G, Bandra Kurla Complex, Bandra (E), Mumbai - 400 051 SYMBOL: JSL	To, Head of the Department, Department of Listing Operation, <b>BSE Limited</b> Phiroze Jeejeebhoy Towers, Dalal Street, Mumbai 400001 SCRIP Code: 544476
--	---

**Subject: Intimation under Regulation 30 of SEBI (Listing Obligations and Disclosure Requirements) Regulations, 2015 – Publication of Case Report.**

Pursuant to Regulation 30 of the SEBI (Listing Obligations and Disclosure Requirements) Regulations, 2015, we wish to inform you that a case report has been published in the "*Ayush Journal of Integrative Oncology*".

The said publication has been authored by medical professionals associated with the Company, including our Managing Director, senior consultants, and Ayurvedic experts. This publication reflects the Company's continued commitment towards the advancement of Ayurvedic research and the promotion of evidence-based clinical practices.

The details of the publication are as under:

S. No.	Type	Title of Publication
1.	Case Report	<i>One-year disease-free resolution of recurrent mildly metabolically active left supraclavicular lymphadenopathy of infective etiology in a post-mastectomy breast cancer survivor through Ayurveda: A positron emission tomography-computed tomography documented case report</i>

The above-mentioned case report has been co-authored by **Acharya Manish Grover Ji (Managing Director)** along with the following medical professionals associated with the Company: **Gitika Chaudhary, Richa, Rahul K. Singh, Tanu Rani, and V. P. Sreekutty**.

A copy of the published article is enclosed herewith as **Annexure-A** for your information and records.

Thanking you,

**Yours faithfully,**  
**For Jeena Sikho Lifecare Limited**

**Manish Grover**  
**Managing Director**  
**DIN: 07557886**

**Place: Zirakpur, Punjab**  
**Date: 22.01.2026**

**JEENA SIKHO LIFECARE LIMITED**

120+ AYURVEDA CLINICS & HOSPITALS | FREEDOM FROM 2D DISEASES & DRUGS

**Registered Office Address:**

SCO-11, Kalgidhar Enclave, Baltana, Zirakpur,  
Punjab-140604, 01762-513185  
CIN NO: L52601PB2017PLC046545

**Corporate Office Address:**

B-26, Opp. Metro Pillar No. 223, Rohtak Road,  
New Multan Nagar, Delhi - 110056  
Email ID: cs@jeenasikho.com | www.jeenasikho.com

## Case Report

# One-year disease-free resolution of recurrent mildly metabolically active left supraclavicular lymphadenopathy of infective etiology in a postmastectomy breast cancer survivor through Ayurveda: A positron emission tomography-computed tomography documented case report

Acharya Manish, Gitika Chaudhary, Richa, Rahul K. Singh, Tanu Rani, V. P. Sreekutty

Department of Research and Development, Jeena Sikho Lifecare Limited, Zirakpur, Punjab, India

## Abstract

Breast carcinoma is one of the leading malignancies among women, often associated with long-term physical and psychological challenges. This report presents the case of a 53-year-old female diagnosed with carcinoma of the left breast in 2019, who underwent six cycles of chemotherapy, mastectomy, and radiotherapy. In November 2020, she received neoadjuvant chemotherapy followed by modified radical mastectomy and postoperative radiotherapy, with the last session completed in January 2021. In February 2023, positron emission tomography-computed tomography revealed a left supraclavicular lymph node suggestive of reactive lymphadenopathy. The patient subsequently developed right upper limb swelling, chest wall pain, and generalized weakness, leading her to seek *Ayurvedic* care in March 2023. *Ayurvedic* interventions, including personalized therapies, dietary, and lifestyle modifications, were initiated. Follow-up evaluations showed steady improvement – partial response by June 2023, minor but nonconcerning changes in February 2024, and complete resolution of the disease by July 2024, which remained stable through December 2024. This case demonstrates that *Ayurveda*, through its holistic and personalized approach, holds significant potential not only in providing symptomatic relief but also in addressing the chance of cancer recurrence, thereby offering a ray of hope for cancer survivors.

**Keywords:** *Arbuda*, Ayurveda, carcinoma breast, positron emission tomography-computed tomography scan, postcancer care

**Address for correspondence:** Dr. Gitika Chaudhary, Department of Research and Development, Jeena Sikho Lifecare Limited, Zirakpur, Punjab, India.

E-mail: shuddhi.research@jeenasikho.co.in

**Submitted:** 27-09-2025, **Revised:** 01-11-2025, **Accepted:** 20-11-2025, **Published:** 31-12-2025.

## INTRODUCTION

Breast cancer remains the most prevalent malignancy among women globally, posing significant health challenges. In 2022, approximately 2.3 million women were diagnosed with breast cancer worldwide, with 670,000 succumbing

to the disease. In India, breast cancer has emerged as the most common cancer among women, with an age-standardized incidence rate of 32.0 per 100,000

This is an open access article distributed under the terms of the Creative Commons Attribution-NonCommercial-NoDerivatives 4.0 License (CC BY-NC-ND), where it is permissible to download and share the work provided it is properly cited. The work cannot be changed in any way or used commercially without permission from the journal.

**For reprints contact:** WKHLRPMedknow\_reprints@wolterskluwer.com

**How to cite this article:** Manish A, Chaudhary G, Richa, Singh RK, Rani T, Sreekutty VP. One-year disease-free resolution of recurrent mildly metabolically active left supraclavicular lymphadenopathy of infective etiology in a postmastectomy breast cancer survivor through Ayurveda: A positron emission tomography-computed tomography documented case report. *Ayush J Integr Oncol* 2025;2:267-75.

### Access this article online

#### Quick Response Code:



#### Website:

<https://journals.lww.com/AJIO/>

#### DOI:

10.4103/ajio.ajio\_49\_25

women. The age-standardized mortality rate stands at 15.1 per 100,000 women, reflecting the substantial burden of this disease.<sup>[1]</sup>

Despite advancements in conventional treatments such as surgery, chemotherapy, and radiotherapy, many patients continue to experience persistent symptoms and a diminished quality of life posttreatment. Integrative approaches, including Ayurveda, offer potential in addressing these challenges by focusing on holistic healing and individualized care.<sup>[2]</sup>

In the *Ayurvedic* perspective, breast cancer can be correlated with *Granthi* (benign growths) and *Arbuda* (malignant tumors), conditions arising from an imbalance in the *Tridoshas*—*Vata*, *Pitta*, and *Kapha*—along with derangements in *Rakta* (blood), *Mamsa* (muscle tissue), and *Meda* (adipose tissue). The accumulation of *Ama* (toxins) due to impaired *Agni* (digestive/metabolic fire) is considered a significant contributory factor, leading to aberrant cellular activity and pathological tissue growth. All ailments related to the female breast are collectively referred to as *Stana Roga*. Conditions such as *Stana Vidradhi* (abscess), *Stana Keelaka* (nodules), and *Stana Rujja* (pain) are described in the classical texts as *Stanashritha Vyadhi* (diseases localized to the breast).<sup>[3-5]</sup> Management of such conditions in *Ayurveda* involves a multidimensional approach, including *Shodhana* (detoxification), *Shamana* (palliative care), *Rasayana* (rejuvenation therapy), and lifestyle modifications aimed at restoring *doshic* balance and promoting holistic well-being. Emerging evidence highlights the potential of integrative *Ayurvedic* interventions to enhance the quality of life and mitigate treatment-related side effects in cancer patients.<sup>[6]</sup>

## Objective

This case report describes a 53-year-old woman with left breast carcinoma, highlighting her posttreatment recovery and the targeted *Ayurvedic* interventions used to manage residual symptoms and enhance quality of life. As shown in Table 1, Clinical and ayurvedic examination findings of the patient.

## CASE REPORT

A 53-year-old female was diagnosed with carcinoma of the left breast in 2019 and underwent 6 cycles of chemotherapy, mastectomy, and 2 cycles of postoperative radiotherapy, followed by a modified radical mastectomy (MRM) in 2020 with subsequent adjuvant treatments. She remained under conventional oncology care until 2022. In February 2023, a positron emission tomography-computed

tomography (PET-CT) scan revealed a left supraclavicular lymph node (1.2 cm × 0.9 cm) suggestive of reactive lymphadenopathy, raising concern for recurrence. Subsequently, the patient developed posttreatment symptoms including right upper limb swelling and pain, tenderness and heaviness in the left chest wall, generalized weakness, white patches and hyperacidity, as summarized in Table 2. To address these persistent complaints and improve her overall quality of life, she sought Ayurvedic management at Jeena Sikho Lifecare Limited, Safdarjung, Delhi. The patient received day-care treatment from March 14 to March 29, 2024.

**Table 1: Clinical and ayurvedic examination findings of the patient**

Parameter	Findings
<b>Blood Pressure</b>	120/80 mm of Hg
<b>Pulse Rate</b>	108/min
<b>CNS</b>	Conscious, well oriented
<b>CVS</b>	S1S2 clear
<b>SPO2</b>	94%
<b>Weight</b>	71 kg
<b>Nadi (Pulse)</b>	<i>Vataj Pittaj</i> predominant
<b>Mala (Stool)</b>	<i>Prakrit</i> (Clear)
<b>Mutra (Urine)</b>	<i>Prakrit</i> (Clear)
<b>Jivha (Tongue)</b>	<i>Saam</i> (Mild coated)
<b>Shabda (Voice)</b>	<i>Spashta</i> (Clear)
<b>Sparsha (Touch)</b>	<i>Anushna Sheet</i> (Normal)
<b>Akriti (Physique)</b>	<i>Madhyam</i>
<b>Drik (Eye)</b>	<i>Prakrit</i> (Clear)
<b>Kshudha (Appetite)</b>	<i>Alpa</i> (Less)
<b>Agni (Digestive fire)</b>	<i>Mandya</i> (Less)
<b>Nidra (Sleep)</b>	<i>Khandit</i> (Disturbed)

**Table 2: The clinical history**

Date / Year	Event / Clinical Detail
2019	- Diagnosed with left carcinoma breast (CA breast).
	- Underwent six cycles of chemotherapy.
	- Left mastectomy performed.
	- Received postoperative radiotherapy.
Nov-20	After neoadjuvant chemotherapy (NACT), underwent Modified Radical Mastectomy (MRM).
Jan-21	- Followed by postoperative radiotherapy.
January 2021-2022	Post CT/RT Trastuzumab
February 20, 2023	PET-CT scan: Left supraclavicular lymph node measuring 1.2 × 0.9 cm, suggestive of Reactive Lymphadenopathy.
March 14, 2023	- Right upper limb swelling and pain
	- Tenderness and pain in left chest wall
	- Generalized weakness
	- Hyperacidity
Obstetric History	- White patches
	Mother of three live children, no history of abortion.
Menstrual History	Menopause 2021.

## Treatment plan

### Diet plan [Table 3]

The patient's diet was strategically designed to support cancer management, enhance recovery, and mitigate treatment-related side effects, focusing on nutritional adequacy and immune support.<sup>[1,7]</sup>

### Lifestyle guidelines [Table 4]

A circadian dietary intervention plan aligns meal timing and composition with the body's internal biological clock to optimize metabolism, digestion, and hormonal balance. This structured meal approach emphasizes nutrient-dense foods consumed at biologically appropriate times to enhance overall health and disease prevention.

### Ayurveda procedures administered to the patient [Table 5]

Ayurvedic procedures were administered based on the patient's Prakriti and disease condition, aiming to restore Dosha balance and enhance systemic detoxification. These therapies supported holistic healing by improving digestion, circulation, and overall physiological harmony.

**Table 3: Dietary intervention plan and meal structure (Circadian D.I.P. diet)**

<b>Restricted Foods:</b>	The diet excluded wheat, processed foods, dairy, non-vegetarian items, caffeinated beverages (coffee, tea), and meals after 8 PM.
<b>Fluid Intake:</b>	Daily intake of alkaline water, herbal infusions, almond and coconut milk, coconut water, and turmeric-infused water was encouraged.
<b>Millets:</b>	Five types of millets—foxtail, barnyard, little, kodo, and browntop—were incorporated, prepared in stainless steel cookware.
<b>Planned Meal Structure (Circadian D.I.P. Diet):</b>	Meals were consumed within a 10-hour window (8:00 AM–6:00 PM) to enhance metabolic health
	<b>Early Morning:</b> Curry leaves, herbal tea, fresh ginger, and turmeric.
	<b>Breakfast:</b> Seasonal fruits, steamed sprouts, and fermented millet-based beverages.
	<b>Lunch:</b> Millet-based dishes with steamed vegetable salads or sprouts. Salad quantities were adjusted to five times the patient's weight.
	<b>Snacks:</b> Red and green juices, and soaked almonds.
	<b>Dinner:</b> Steamed vegetable salad or sprouts, excluding additional cooked millet dishes.

**Table 4: Daily lifestyle and wellness practices for holistic health promotion**

<b>1. Morning Sun Exposure:</b>	Spend 30 minutes daily in early sunlight to boost vitamin D and overall health.
<b>2. Yoga Practice:</b>	Engage in one hour of yoga daily for physical and mental well-being.
<b>3. Mindfulness:</b>	Practice meditation regularly to reduce stress and enhance emotional balance.
<b>4. Barefoot Walking:</b>	Walk barefoot on natural surfaces for 30 minutes to improve circulation and connect with nature.
<b>5. Sleep Hygiene:</b>	Prioritize 7–8 hours of quality sleep nightly for recovery and rejuvenation.
<b>6. Structured Routine:</b>	Follow a consistent daily schedule to promote balance and harmony.

### Medicinal intervention

The *Ayurvedic* treatment protocol for this case incorporated a range of specialized *Ayurvedic* formulations in conjunction with *Panchakarma* therapies. Table 6 provides a comprehensive overview of these medicines, detailing their composition, duration of administration, and specific therapeutic applications.

The patient returned for a follow-up on June 2, 2023, with no new complaints. The patient attended follow-ups on July 19, 2023, August 14, 2023, October 28, 2023, January 21, 2024, and February 27, 2024.

## RESULTS

The patient was a 53-year-old female with a history of left breast carcinoma who sought for postoperative/treatment cancer care. The PET-CT scan results are mentioned in Table 7. The conditions before and after treatment are mentioned in Table 8.

## DISCUSSION

This case report highlights the *Ayurvedic* approach to managing posttreatment symptoms in a 53-year-old female patient with a history of left breast carcinoma. Despite the advancements in conventional cancer therapies, including chemotherapy, surgery, and radiotherapy, many patients continue to experience persistent symptoms that significantly impact their quality of life. This case underscores the importance of exploring complementary therapies, such as Ayurveda, to address these challenges.

The following flowchart outlines the *Dosha-Dushya-Srotas* involvement, contributing to the manifestation and *Samprapti* of the disease in this patient [Figure 2]. The *Samprapti* of *Arbuda* begins with *Nidana Sevana*, leading to *Kapha-Vata* aggravation that affects *Rasa*, *Rakta*, and *Mamsa Dhatus*, causing obstruction in *Rasa*, *Mamsa*, and *Artava Vaha Srotas*. This obstruction results in *Arbuda* formation, and even after its removal, residual *Dosha* imbalance can cause pain aggravation and lymphatic congestion (*Uttara Lakshana*).

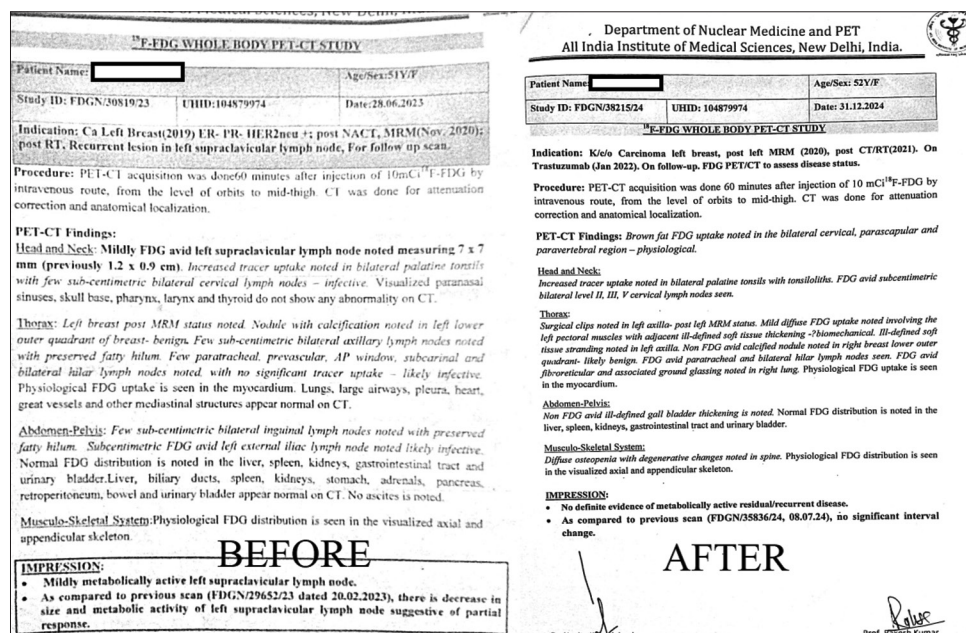
The *Ayurvedic* principles aimed to restore balance within the body and promote holistic healing, addressing not only the physical symptoms but also the emotional and psychological aspects of recovery.

The *Ayurvedic* therapeutic modalities of *Sarvanga Snehana*, *Anagaha Swedana*, *Sadhya Vamana*, *Basti*, and *Shirodhara* collectively contribute to the restoration of holistic health and well-being. *Sarvanga Snehana* facilitates tissue



Table 5: Types of associated congenital anomalies in the study population

Therapy	Procedure
<b>Abhyagam with Kottamchukkadi Tail</b>	<i>Sarvang Snehana</i> (full-body oleation) involves the external application of warm <i>Kottamchukkadi Taila</i> over the entire body with gentle, rhythmic massage. This therapy is performed for a specific duration, using long, smooth strokes following the anatomical alignment of muscles and lymphatic flow.
<b>Avagaha Sweda with Dashmoola and Punarnava Kwath</b>	<i>Avagaha Sweda</i> involves immersing the patient in a warm decoction of <i>Dashmoola</i> (a group of ten roots) and <i>Punarnava</i> ( <i>Boerhavia diffusa</i> ). The prepared medicated decoction is poured into a tub, and the patient is seated comfortably, ensuring the affected areas are submerged. The duration typically lasts 15–30 minutes, depending on the patient's condition.
<b>Shirodhara with Brahmi and Ksheerbala Oil on alternate day</b>	<i>Shirodhara</i> involves the continuous, rhythmic pouring of lukewarm <i>Brahmi</i> ( <i>Bacopa monnieri</i> ) and <i>Ksheerbala</i> oil over the forehead, particularly targeting the <i>Ajna Marma</i> (forehead energy point). The patient lies in a supine position, and the process lasts for 30–45 minutes, conducted in a calm environment to promote relaxation.
<b>Sadhya Vaman</b>	In this patient, <i>Sadhya Vamana</i> was administered following preparatory procedures of <i>Snehana</i> (oleation) and <i>Swedana</i> (fomentation). Emetic herbs like <i>Madanphala</i> ( <i>Randia dumetorum</i> ) were given to induce therapeutic vomiting. Under supervision, emesis was performed until the desired <i>Kapha</i> elimination was achieved. Post-procedure care ( <i>Sansarjana Krama</i> ) included a light, easily digestible diet to restore <i>Agni</i> (digestive fire) and balance.
<b>Lekhana Basti</b>	<i>Lekhana Basti</i> is a specialized enema therapy administered with medicated decoctions and oils containing herbs like <i>Triphala</i> , <i>Trikatu</i> , <i>Dashmoola</i> , <i>Punarnava</i> , and <i>Musta</i> . After preparation through <i>Snehana</i> (oleation) and <i>Swedana</i> (fomentation), the medicated enema is introduced into the rectum. The patient retains the enema for a specified duration, allowing the active ingredients to act locally and systemically.



**Figure 1:** Positron Emission Tomography–Computed Tomography (PET-CT) scan showing metabolic and anatomical assessment of the affected regions. The fused PET-CT images demonstrate areas of altered radiotracer uptake correlating with structural changes, aiding in disease evaluation and treatment response assessment

**Table 6: Ayurvedic medications, ingredients, duration, and therapeutic effects in the management of posttonsillectomy care for Tonsillar lymphoma**

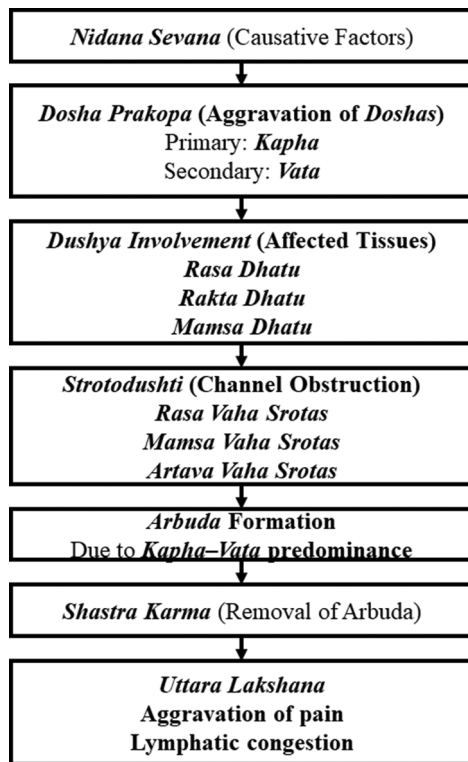
Medicine Name	Ingredients	Duration	Therapeutic Effects
<b>Carcinex Capsule</b>	<b>Guduchi powder</b> ( <i>Tinospora cordifolia</i> ), <b>Kirattikta powder</b> ( <i>Andrographis paniculata</i> ), <b>Maricha powder</b> ( <i>Piper nigrum</i> ), <b>Paneer Dodi powder</b> ( <i>Hedychium spicatum</i> ), <b>Amlaki rasayan powder</b> ( <i>Phyllanthus emblica</i> ), <b>Tamra bhasma powder</b> , <b>Swarnamakshik Bhasma</b> , <b>Kalmegha</b> ( <i>Andrographis paniculata</i> ), <b>Neem powder</b> ( <i>Azadirachta indica</i> ), <b>Lavang powder</b> ( <i>Syzygium aromaticum</i> ), <b>Abhrak Bhasma powder</b>	14/03/2023 to 06/01/2025	Used for <i>Arbuda</i> (tumors), <i>Granthi</i> (cysts/nodules), <i>Raktadushti</i> (blood impurity), <i>Shoth har</i> (anti-inflammatory), <i>Vishanashaka</i> (detoxifier/anti-poison), <i>Balya</i> (strengthening), <i>Lekhana</i> (scraping/reducing excess tissue or fat), and <i>Rasayan</i> (rejuvenative).
<b>Maha Granthi Har Vati</b>	<b>Parad Bhasam</b> (Mercury), <b>Gandhak</b> (Sulfur), <b>Vang Bhasam</b> (Zinc), <b>Taabr Bhasam</b> (Copper), <b>Kash Bhasam</b> (Potassium), <b>Hartal Bhasam</b> (Realgar), <b>Nilla Thotha</b> (Copper sulfate), <b>Shankh Bhasam</b> (Conch shell powder), <b>Kodi Bhasam</b> (Cuttlefish bone), <b>Loh Bhasam</b> (Iron), <b>Sonth</b> ( <i>Zingiber officinale</i> ), <b>Kalimirch</b> ( <i>Piper nigrum</i> ), <b>Pippal</b> ( <i>Piper longum</i> ), <b>Harad</b> ( <i>Terminalia chebula</i> ), <b>Bahera</b> ( <i>Terminalia bellirica</i> ), <b>Amla</b> ( <i>Phyllanthus emblica</i> ), <b>Chavya</b> ( <i>Piper chaba</i> ), <b>Kachur</b> ( <i>Curcuma zedoaria</i> ), <b>Vayavdanga</b> ( <i>Tribulus terrestris</i> ), <b>Pippal Mool</b> ( <i>Piper longum</i> root), <b>Patha</b> ( <i>Cyclea peltata</i> ), <b>Hau Ber</b> ( <i>Ziziphus mauritiana</i> ), <b>Vacha</b> ( <i>Acorus calamus</i> ), <b>Choti Ilaychi</b> ( <i>Elettaria cardamomum</i> ), <b>Devdaru</b> ( <i>Cedrus deodara</i> ), <b>Samundar Namak</b> (Rock salt), <b>Senda Namak</b> (Sendha salt), <b>Sambar Namak</b> (Sambhar salt), <b>Vid Namak</b> (Black salt), <b>Kala Namak</b> (Black salt), <b>Vidari</b> ( <i>Pueraria tuberosa</i> ).	14/03/2023 to 06/01/2025	<i>Granthi/Arbud</i> (Cyst/Tumor), <i>Lekhana</i> (Scraping/Reducing excess tissue), <i>Shoth har</i> (Anti-inflammatory), <i>Raktashodhak</i> (Blood purifier), <i>Vedanasthapana</i> (Pain reliever)
<b>Granthi Har Vati</b>	<b>Kachnar</b> ( <i>Bauhinia variegata</i> ), <b>Guggul</b> ( <i>Commiphora wightii</i> ), <b>Amalki</b> ( <i>Phyllanthus emblica</i> ), <b>Vibhitik</b> ( <i>Terminalia bellirica</i> ), <b>Haritiki</b> ( <i>Terminalia chebula</i> ), <b>Shunti</b> ( <i>Zingiber officinale</i> ), <b>Marich</b> ( <i>Piper nigrum</i> ), <b>Pippal</b> ( <i>Piper longum</i> ), <b>Varuna</b> ( <i>Crateva religiosa</i> ), <b>Sukshamala</b> , <b>Dalchini</b> ( <i>Cinnamomum verum</i> ), and <b>Tamal Patar</b> ( <i>Cinnamomum tamala</i> )	14/03/2024 to 06/01/2025	<i>Lekhana</i> (scraping), <i>Stambhana</i> (astringent), <i>Shoth har</i> (anti-inflammatory), <i>Vedanasthapana</i> (analgesic), <i>Kapha-Vata Shaman</i> (pacifying <i>Kapha</i> and <i>Vata doshas</i> ).
<b>Immune Power Syrup</b>	<b>Giloy</b> ( <i>Tinospora cordifolia</i> ), <b>Nag Kesar</b> ( <i>Mesua ferrea</i> ), <b>Dashmool</b> , <b>Babool</b> ( <i>Vachellia nilotica</i> ), <b>Dhatoora</b> ( <i>Datura stramonium</i> ), <b>Magha</b> ( <i>Madhuca longifolia</i> ), <b>Vasa</b> ( <i>Adhatoda vasica</i> ), <b>Jaifal</b> ( <i>Myristica fragrans</i> ), <b>Mulethi</b> ( <i>Glycyrrhiza glabra</i> ), <b>Long</b> ( <i>Syzygium aromaticum</i> ), <b>Choti Kateri</b> ( <i>Solanum xanthocarpum</i> ), <b>Kankol</b> ( <i>Piper cubeba</i> ), <b>Talispatr</b> ( <i>Abies webbiana</i> ), <b>Badi Elachi</b> ( <i>Elettaria cardamomum</i> ), <b>Madhu</b> , <b>Dalchini</b> ( <i>Cinnamomum verum</i> ), <b>Tejpatr</b> ( <i>Cinnamomum tamala</i> ), <b>Mahua</b> ( <i>Madhuca longifolia</i> ), <b>Kali Mirch</b> ( <i>Piper nigrum</i> ), and <b>Shaker</b> ( <i>Saccharum officinarum</i> ).	14/03/2024 to 06/01/2025	<i>Ojas Vardhaka</i> (immune booster), <i>Rasayana</i> (Rejuvenator), <i>Vyadhi Kshamatva</i> (immunity), <i>Shoth har</i> (Anti-inflammatory), <i>Deepan</i> (Digestive stimulant), <i>Balya</i> (Strengthened)

Contd...

Table 6: Contd...

<b>Go Flexi</b>	<b>Paneer Dodi</b> ( <i>Withania coagulans</i> ), <b>Ashwagandha</b> ( <i>Withania somnifera</i> ), <b>Amalaki Rasayan</b> ( <i>Phyllanthus emblica</i> ), <b>Yograj Guggulu</b> ( <i>Commiphora mukul</i> – main ingredient), <b>Methi</b> ( <i>Trigonella foenum-graecum</i> ), <b>Shankh Bhasm</b> (Incinerated Conch Shell), <b>Gokshuru</b> ( <i>Tribulus terrestris</i> ), <b>Punarnava</b> ( <i>Boerhavia diffusa</i> ), <b>Nirgundi</b> ( <i>Vitex negundo</i> ), <b>Haldi</b> ( <i>Curcuma longa</i> ), <b>Neem</b> ( <i>Azadirachta indica</i> ).	14/05/2023 to 06/01/2025	<b>Sandhi-Shoth har</b> (Anti-inflammatory for joints), <b>Vedanasthapana</b> (Analgesic/Pain reliever), <b>Balya</b> (Strength-promoting), <b>Vata-kaphahara</b> (Pacifier of <i>Vata</i> and <i>Kapha</i> ), <b>Rasayana</b> (Rejuvenation therapy), <b>Shoth har</b> (Anti-inflammatory), <b>Mutral</b> (Diuretic), <b>Shoola-praShaman</b> (Pain alleviator), <b>Agnideepan</b> (Stimulator of digestive fire), <b>Ama Pachan</b> (Toxin digester)
<b>Arogya Vati</b>	<b>Kajan</b> ( <i>Carthamus tinctorius</i> ), <b>Loh Bhasm</b> ( <i>Ferrum</i> ), <b>Abhrak Bhasm</b> ( <i>Mica</i> ), <b>Tamra Bhasm</b> (Copper), <b>Amalaki</b> ( <i>Embllica officinalis</i> ), <b>Vibhitak</b> ( <i>Terminalia bellirica</i> ), <b>Haritaki</b> ( <i>Terminalia chebula</i> ), <b>Chitrak</b> ( <i>Plumbago zeylanica</i> ), <b>Katuka</b> ( <i>Picrorhiza kurroa</i> ), <b>Nimb Patra</b> ( <i>Azadirachta indica</i> )	06-01-2025	<b>Rasayana</b> (Rejuvenator), <b>Vata-Pitta Shaman</b> (Pacifier of <i>Vata</i> and <i>Pitta doshas</i> ), <b>Deepan</b> (Digestive stimulant), <b>Pachan</b> (Digestive/metabolism enhancer), <b>Balya</b> (Strengtheners)
<b>Orthonil tonic</b>	<b>Devdaru</b> ( <i>Cedrus deodara</i> ), <b>Dhania</b> ( <i>Coriandrum sativum</i> ) and <b>Peepal</b> ( <i>Ficus religiosa</i> )	12/05/2024 to 06/01/2025	<b>Vata shamaka</b> ( <i>Vata</i> pacifier), <b>Shoth har</b> (Anti-inflammatory), <b>Rasayana</b> (Rejuvenator), <b>Balya</b> (Strengtheners), <b>Shulahara</b> (Pain reliever)
<b>Sandhi Arogya Vati</b>	<b>Sonth</b> ( <i>Zingiber officinale</i> ), <b>Syah Jeera</b> ( <i>Carum carvi</i> ), <b>Shilajeet</b> ( <i>Asphaltum</i> ), <b>Abhrak Bhasma</b> ( <i>Muscovite</i> ), <b>Ashwagandh</b> ( <i>Withania somnifera</i> ), <b>Shallaki</b> ( <i>Boswellia serrata</i> ), <b>Guggul</b> ( <i>Commiphora wightii</i> ), <b>Yavani</b> ( <i>Trachyspermum ammi</i> ), <b>Chandrasoor</b> ( <i>Lepidium sativum</i> ), <b>Rason</b> ( <i>Allium sativum</i> ), <b>Nirgundi</b> ( <i>Vitex negundo</i> ), <b>Hemvati</b> ( <i>Berberis aristata</i> ), <b>Suranjan</b> ( <i>Colchicum autumnale</i> ), <b>Parijat</b> ( <i>Nyctanthes arbor-tristis</i> ), <b>Vaya Vidang</b> ( <i>Embelia ribes</i> ).	13-03-2024	<b>Vata-kapha shamaka</b> ( <i>Dosha</i> -balancer), <b>Shoth har</b> (Anti-inflammatory), <b>Vatahara</b> ( <i>Vata</i> pacifier), <b>Rasayana</b> (Rejuvenator), <b>Balya</b> (Strengtheners)
<b>Nervine Tonic</b>	<b>Balarishta</b> , <b>Ashwagandharishta</b> and <b>Saraswatarishta</b>	13-03-2024	<b>Medhya Rasayana</b> (nootropic & rejuvenative), <b>Manas Shamak</b> (calms the mind), <b>Satvavajaya Chikitsa</b> (promotes mental strength), <b>Manasika Bala</b> (mental strength), <b>Balya</b> (strength-promoting), <b>Vatahara</b> ( <i>Vata</i> -pacifying), <b>Ama Pachana</b> (removal of toxins), <b>Vata Anulomaka</b> (corrector of <i>Vata</i> imbalance) and <b>Satva-sthirikara Rasayana</b> (stabilizer of mental strength)





**Figure 2:** The *Samprapti* of this case

nourishment, promotes systemic detoxification, and alleviates stress through its calming effect on the nervous system.<sup>[10]</sup> *Avagaha Swedana*, which involves immersion in a warm medicated decoction, enhances peripheral circulation, reduces inflammation, and assists in the elimination of toxins, thereby mitigating pain and stiffness.<sup>[11]</sup> *Sadhya Vamana*, a therapeutic emesis procedure, aids in the expulsion of accumulated *Ama* (metabolic toxins), thereby improving digestive function and promoting systemic rejuvenation.<sup>[12]</sup> *Basti*, the administration of medicated enemas, is considered a potent cleansing intervention that balances the *Doshas*, supports nutrient assimilation, and strengthens gastrointestinal health.<sup>[13]</sup> *Shirodhara*, characterized by the continuous pouring of warm medicated oil over the forehead, induces mental calmness, alleviates anxiety, enhances cognitive clarity, and fosters emotional equilibrium.<sup>[14]</sup>

A wide range of *Ayurvedic* ingredients, each defined by its *Ras Panchaka*, contribute to the management of *Arbuda*, *Granthi*, *Sandhivata*, and related disorders. *Guduchi*, *Amalaki*, and *Triphala* act as *Rasayanas* with *Raktasodhaka* and *Vyadhi Kshamatva* properties<sup>[15-17]</sup> which can be correlated with modern immunomodulatory, antioxidant, and cytoprotective effects that enhance tissue repair and immune surveillance. *Kalmegha*, *Kirattikta*, and *Trikatu* enhance *Agni*, promote *Ama Pachana*, and reduce inflammation,<sup>[18-20]</sup> corresponding to improved metabolic

**Table 7:** The Positron emission tomography-computed tomography scan reports [Figure 1]

Date	Event/Visit Type	PET-CT / Clinical Findings	Comparison / Impression
20-02-2023	PET-CT (baseline)	Left supraclavicular lymph node present.	Baseline reference.
28-06-2023	PET-CT	Mildly metabolically active left supraclavicular lymph node.	Decrease in size and metabolic activity compared to 20-02-2023 → <b>Partial response</b> .
19-02-2024	PET-CT	Metabolically active nodular heterogeneity in left pectoralis major muscle (new finding).	New finding vs. 04-10-2023; Metabolically active nodular heterogeneity in left pectoralis major muscle.
08-07-2024	PET-CT	No evidence of metabolically active residual/recurrent disease.	Further reduction in FDG uptake in left pectoral muscles vs. 19-02-2024.
31-12-2024	PET-CT	No evidence of metabolically active residual/recurrent disease.	No significant interval change vs. 08-07-2024.

**Table 8:** The conditions before and after treatment

Condition	Before Treatment	After Treatment
Right upper limb swelling & pain <sup>[8]</sup>	Present, causing discomfort	Relieved
Tenderness in left chest wall	Marked tenderness & pain	Significant reduction
Generalized weakness <sup>[9]</sup>	Moderate	Improved
Hyperacidity	Frequent complaints	Symptoms subsided
White patches	Noted	Improved

detoxification, anti-inflammatory, and hepatoprotective actions. Mineral preparations such as *Tamra*, *Abhrak*, and *Lob Bhasma* exhibit *Teeksbha-Ushna Virya* and *Lekhana* qualities, supporting detoxification and blood purification,<sup>[21]</sup> which parallel modern evidence on their trace-element mediated antioxidant and hematinic roles. *Kachnar*, *Varuna*, *Punarnava*, and *Neem* aid in *Lekhana*, *Kapha-Vata Shamana*, and *Mutral* actions, addressing cystic growths and edema,<sup>[22-25]</sup> correlating with antiproliferative, diuretic, and lymphatic-draining effects recognized in modern research. For strength and immunity, *Ashwagandha* and *Shilajit* provide *Balya* and *Shothahara* effects, while *Haldi* offers *Vishagbha* and anti-inflammatory benefits,<sup>[26,27]</sup> aligning with adaptogenic, anti-inflammatory, and immunoregulatory mechanisms. Neuroprotective formulations like *Saraswatarishta*, *Balarishta*, and *Ashwagandharishta* serve as *Medhya Rasayanas*, calming the mind and enhancing cognitive strength, paralleling neuroprotective and anxiolytic properties demonstrated in modern neuropharmacology.

Moreover, the *Ayurvedic* perspective on cancer, which correlates breast carcinoma with imbalances in the *Tridoshas* and derangements in bodily tissues, provides a unique framework for understanding and addressing the complexities of postcancer recovery.

### Need for further research

Further research is essential to validate the efficacy and safety of *Ayurvedic* interventions in oncology care,



particularly in the context of postcancer recovery. While this case report highlights promising outcomes associated with *Ayurvedic* therapies, larger, controlled clinical trials are necessary to establish standardized treatment protocols and assess their impact on diverse patient populations.

## CONCLUSION

A 53-year-old female was diagnosed with carcinoma of the left breast in 2019 and underwent chemotherapy, mastectomy, radiotherapy, and later an MRM with adjuvant therapy, followed by trastuzumab until 2022. Despite completing conventional oncology care, she continued to experience posttreatment complaints and side effects of chemotherapy, which significantly affected her quality of life. Seeking further relief, she opted for *Ayurvedic* management.

In early 2023, she presented with right upper limb swelling and pain, tenderness in the left chest wall, generalized weakness, hyperacidity, and white patches. She received day-care *Ayurvedic* therapy from March 14 to March 29, 2024.

Following treatment, the patient reported substantial improvement. Right upper limb swelling and pain were completely relieved, generalized weakness improved, hyperacidity complaints subsided, tenderness in the left chest wall was significantly reduced, and white patches showed marked improvement.

Serial PET-CT imaging also documented her progress. The baseline scan in February 2023 revealed a left supraclavicular lymph node with partial metabolic response by June 2023. A heterogeneous uptake was noted in February 2024, though subsequent scans in July and December 2024 demonstrated no evidence of metabolically active residual or recurrent disease, suggesting stable remission.

The *Ayurvedic* interventions in this case effectively alleviated posttreatment symptoms and chemotherapy-related side effects, while also contributing to favorable PET-CT findings that indicated both clinical and systemic improvement.

## Declaration of patient consent

The authors certify that they have obtained all appropriate patient consent forms. In the form, the patient has given her consent for her images and other clinical information to be reported in the journal. The patient understands that name and initial will not be published and due efforts will be made to conceal identity, but anonymity cannot be guaranteed.

## Financial support and sponsorship

Nil.

## Conflicts of interest

There are no conflicts of interest.

## REFERENCES

1. World Health Organization. Breast Cancer Fact Sheet. Geneva: World Health Organization; 2025. Available from: <https://www.who.int/news-room/fact-sheets/detail/breast-cancer>. [Last accessed on 2025 Jan 16].
2. National Center for Biotechnology Information. Bethesda (MD): National Center for Biotechnology Information; 2025. Available from: <https://pmc.ncbi.nlm.nih.gov/articles/PMC11101532/>. [Last accessed on 2025 Jan 16].
3. Sharma S, editor. Ashtanga Samgraha of Vahata or Vruddha Vagbhata with Sasilekha Sanskrit commentary. Varanasi: Chaukhamba Sanskrit Series Office; 2006. p. 395, 397.
4. Paradkar H, editor. Ashtangahrudaya. 2017<sup>th</sup> ed. Varanasi: Chaukhamba Surabharati Prakashan; 2016. p. 506.
5. Tewari PV. Kashyapa Samhita or Vruddha Jeevakeeya Tantra. Varanasi: Choukhamba Vishwabharati; 2002. p. 13, 15.
6. Koch AK, Patel M, Gupta S, Wullenkord R, Jeitler M, Kessler CS. Efficacy and safety of the Ayurvedic herbal preparation Maharishi Amrit Kalash: A systematic review of randomized controlled trials. *Front Med (Lausanne)* 2024;11:1325037.
7. Manish A, Chaudhary G, Richa, Garima, Sharma N. Management of early-stage breast cancer with Ayurveda: A case study. *Int J AYUSH* 2025;14:89-118.
8. Caraceni A, Shkodra M. Cancer pain assessment and classification. *Cancers (Basel)* 2019;11:510.
9. Given B, Given CW, Sikorskii A, Jeon S, McCorkle R, Champion V, et al. Establishing mild, moderate, and severe scores for cancer-related symptoms: How consistent and clinically meaningful are interference-based severity cut-points? *J Pain Symptom Manage* 2008;35:126-35.
10. Sharma S, Vedpathak S, Kumar V, Patidar A. Review article on Sarvang Abhyang and Swedan. *Int Res J Ayurveda Yoga* 2022;5:144-7. doi:10.47223/IRJAY.2022.5523.
11. Nagawade RS. A review article on Avagaha Sweda. *Int J Res Publ Rev* 2022;3:2296-9.
12. Lodha SG, Karade RS. Role of Sadyovamana as emergency procedure in Panchakarma: A review. *Int J Ayurvedic Med* 2020;11:358-62. Available from: <https://ijam.co.in>. [Last accessed on 2025 Jan 16]. doi:10.47552/ijam.v11i3.1613.
13. Deshmukh V, Sardeshmukh S, Kulkarni A, Gupta V, Gujar S, Sardeshmukh B, et al. Adjunct Ayurvedic treatment providing more than 10 years of disease-free survival in a rare case of male breast cancer patient with high-grade invasive ductal cell carcinoma – A case report. *J Ayurveda Integr Med* 2025;16:100982.
14. Rajan S, Shamkuwar MK, Tanwar AK. Impact of Shirodhara on biological markers of stress: A case study. *J Ayurveda Integr Med* 2021;12:178-81.
15. Muhasina MK, Uddin ME, Mundavath RN, Swaroop AK, Nilewar SS, Mariappan E, et al. Developing a formulation of *Tinospora cordifolia*, identifying its active components, and assessing its anticancer effects on breast cancer cell lines. *Med Oncol* 2025;42:312.
16. Singai C, Pitchakarn P, Taya S, Phannasorn W, Wongpoomchai R, Wongnoppavich A. Chemopreventive potential of *Phyllanthus emblica* fruit extract against colon and liver cancer using a dual-organ rat carcinogenesis model. *Pharmaceuticals* 2024;17:818.
17. Prasad S, Srivastava SK. Oxidative stress and cancer: Chemopreventive and therapeutic role of triphala. *Antioxidants (Basel)* 2020;9:72.

18. Malik Z, Parveen R, Parveen B, Zahiruddin S, Aasif Khan M, Khan A, *et al.* Anticancer potential of andrographolide from *Andrographis paniculata* (Burm.f.) Nees and its mechanisms of action. *J Ethnopharmacol* 2021;272:113936.
19. Karigar SB, M D. A review on Ayurvedic bitter herb – Kiratatikta (*Swertia chirayita* (Roxb.) H. Karst.) – A plant of immense medicinal value. *Int J Res Appl Sci Eng Technol* 2023;11:2255-62.
20. Sharma R, Jadhav M, Choudhary N, Kumar A, Rauf A, Gundamaraju R, *et al.* Deciphering the impact and mechanism of Trikatu, a spices-based formulation on alcoholic liver disease employing network pharmacology analysis and *in vivo* validation. *Front Nutr* 2022;9:1063118.
21. Chatterjee S, Ghosh C, Roy P. Application of Ayurvedic Bhasma for the treatment of cancer. *Indian J Ayurveda Integr Med KLEU* 2024;5:3-12.
22. Tomar P, Dey YN, Sharma D, Wanjari MM, Gaidhani S, Jadhav A. Cytotoxic and antiproliferative activity of kanchnar guggulu, an Ayurvedic formulation. *J Integr Med* 2018;16:411-7.
23. Sharma P, Sudan R, Mishra A, Choudhury A, Sharma N, Kumar K, *et al.* Ayurvedic medicinal plants for cancer treatment: Current insights and future perspectives. *Ayush J Integr Oncol* 2025;2:68-76.
24. Patel N, Mishra R, Rajput D, Gupta A. A comprehensive review of the phytochemistry, pharmacology, pharmacokinetics, and green nanotechnological significance of *Boerhavia diffusa* Linn. *Fitoterapia* 2025;184:106599.
25. Tufail T, Bader Ul Ain H, Ijaz A, Nasir MA, Ikram A, Noreen S, *et al.* Neem (*Azadirachta indica*): A miracle herb; panacea for all ailments. *Food Sci Nutr* 2025;13:e70820.
26. Dhillon D, Jain M, Singh AK, Muthukumaran J. *Withania somnifera*-derived phytochemicals as Bcl-B inhibitors in cancer therapy: A computational approach from byte to bench to bedside. *Biochem Biophys Res Commun* 2025;750:151383.
27. Jambi EJ, Abdulaziz Alshubaily F. Shilajit potentiates the effect of chemotherapeutic drugs and mitigates metastasis induced liver and kidney damages in osteosarcoma rats. *Saudi J Biol Sci* 2022;29:103393.